



PATIENT

Ember Ulen

SPECIES

Canine

BREED

Shetland Sheepdog

SEX

Female Spayed

AGE

11 years

WEIGHT

35.6lbs

INTERPRETED BY

Maggie Machen
Lamy, DVM
DACVIM (Cardiology)

IMAGING PERFORMED BY

Pamela Harrigan,
RDCS

HOSPITAL NAME

Mass Veterinary Services

REFERRING VET

Dr. Masloski

PRESENTING CLINICAL SIGNS

History: Recheck echo. History chronic valvular disease - Stage B1. Current presentation: Ember is doing well at home but does cough occasionally. Good appetite and normal activity level. On exam today: NSR, grade III/VI murmur with PMI left apical area, PSS, lungs clear. BP: 160mmHg x 3.
-Pertinent previous echo findings (11/24/21 Rima Kharbush, DVM, DACVIM-Cardiology): LA 2.91 cm; LA:Ao 1.66; LV 3.56 cm; mild-moderate LAE; moderate MR; normal LV size and function.

ELECTROCARDIOGRAPHIC FINDINGS *Note: Single lead ECGs are evaluated as a rhythm strip. Morphology/MEA cannot be definitively commented on.

A single lead ECG is available; 25mm/s, 20mm/mV. The average heart rate is 110bpm (range 52-167bpm). The rhythm is sinus in origin, with a p for every QRS complex and vice versa. P and QRS morphologies are positive. Frequent VPCs throughout; singles only and monomorphic. Periods of bi- and trigeminy. No ectopic beats, pauses or dysrhythmias observed.

ECG diagnosis: Normal sinus rhythm with respiratory variation. Frequent isolated VPCs.

ECHOCARDIOGRAM FINDINGS

2D, m-mode, color flow and Doppler imaging is available.

Left ventricle: The LV diameter is mildly increased with adequate myocardial function. LV wall thicknesses are normal.

Left atrium: The left atrium is moderately dilated.

Mitral valve: The mitral valve is thickened with mild prolapse into the left atrial lumen. Moderate to severe eccentric mitral regurgitation with a normal velocity.

Aortic valve/Aorta: The aortic valve is normal in morphology and mobility. Normal aortic outflow velocity; laminar flow. No aortic insufficiency.

Right ventricle: No RV dilation.

Right atrium: No RA dilation.

Tricuspid valve: The tricuspid valve is mildly thickened with no tricuspid regurgitation.

Pulmonary valve/Pulmonary artery: The pulmonic valve is normal in morphology and mobility. No pulmonic insufficiency. Normal RVOT velocity; laminar flow.

Pericardium/other: No pericardial or pleural effusion noted. No obvious cardiac masses.

2-Dimensional Measurements

Ao diam (cm)	1.9
LA diam (cm)	3.5
LA:Ao (Swe)	1.8
IVS thickness (cm)	0.8
LVID diastole (cm)	3.6
PW thickness (cm)	0.8
LVID systole (cm)	2.4
FS (%)	33

Doppler Measurements

PV Vmax (m/s)	0.82
AoV Vmax (m/s)	1.1
MR Vmax (m/s)	6.0
TR Vmax (m/s)	NA
TR PG (mmHg)	NA

INVOICE

24025

DATE

5/4/22

INTERPRETATION OF THE FINDINGS

Chronic degenerative valve disease persists with moderate to severe mitral regurgitation. Compared to the measurements in the prior study, there is evidence of progression with moderate left atrial enlargement. This indicates the current risk for complication is low, however there is high risk for progression going forward. No concurrent issues such as



PATIENT
Ember Ulen

systolic dysfunction are noted in this study. Assessment of progression in the future will help predict long term prognosis, which is guarded at this stage (B2). Pimobendan is recommended as below.

SPECIES
Canine

Frequent isolated VPCs are noted on the ECG as well. VPCs are ectopic beats generated from abnormal conductive or fibrotic tissue in the ventricles of the heart muscle, and even frequent single VPCs will often cause no clinical signs in dogs. When sustained however, ventricular tachycardia can lead to symptoms such as lethargy and collapse.

BREED
Shetland Sheepdog

VPCs are a very non-specific finding. They can be primary in origin (arrhythmic disease; a rule out diagnosis), develop secondary to significant cardiac disease, or be extra-cardiac in origin; i.e., due to pain, stress, inflammation, cancer, GI disease, DIC/sepsis, etc. In this senior dog with moderate structural cardiac disease, they are likely due to a combination of stress and structural disease; however, ruling out systemic issues is reasonable (senior labs, AUS, etc.). Unfortunately, there is always an elevated risk for collapse and sudden death in any arrhythmic patient, and even on medications this risk unfortunately still persists.

SEX
Female Spayed

AGE
11 years

In addressing arrhythmias in dogs, we must not only consider why they are happening as above, but also whether or not treatment is warranted. Given only single beats, consider application of a holter monitor if interested in further evaluation. This will tell us the frequency and complexity of the rhythm over 24 hours of normal activity. An alternative approach would be to simply monitor at home for symptoms and utilize a holter monitor should the patient begin to experience clinical signs such as lethargy or collapse, which is also reasonable. No obvious indication for anti-arrhythmic therapy based upon what is seen here. Discussion with the owner is advised.

WEIGHT
35.6lbs

INTERPRETED BY
Maggie Machen
Lamy, DVM
DACVIM (Cardiology)

RECOMMENDATIONS

- Institute Pimobendan 0.25-0.3mg/kg PO q12h.
- Consider holter monitor v monitor at home.
- Consider systemic screening as discussed.
- Omega fatty acid supplementation and mild salt restriction may be of some long-term benefit
- Anesthetic risk is considered moderately elevated. Avoid ketamine, telazol, Dexdomitor (or other alpha-2 agonists) and acepromazine. Recommend having lidocaine CRI available for use in the event of worsening ventricular arrhythmias under anesthesia (CRI 50–75mcg/kg/min). Cardiac protective drug choices (opioid/benzodiazepine premedication, propofol or alfaxalone induction, iso or sevoflurane gas) are recommended. Pre-oxygenate for 5-10 minutes prior to induction and recover in O2 cage. Monitor for arrhythmias, hypotension, and hypoxia both intra and post-operatively and intervene as necessary. Moderate IV fluid restriction is recommended to avoid fluid overload, while considering comorbidities, hydration status, BP, etc.
- Monitor for development of a cough, labored breathing, exercise intolerance or collapse episodes.

IMAGING PERFORMED BY
Pamela Harrigan,
RDCS

HOSPITAL NAME
Mass Veterinary Services

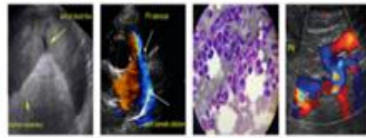
REFERRING VET
Dr. Masloski

INVOICE
24025

DATE
5/4/22

PLAN

- Recommend conservative monitoring with a recheck echocardiogram and ECG in 6 months, sooner if any development of clinical signs.



PATIENT

Ember Ulen

SPECIES

Canine

BREED

Shetland Sheepdog

SEX

Female Spayed

AGE

11 years

WEIGHT

35.6lbs

INTERPRETED BY

Maggie Machen
Lamy, DVM
DACVIM (Cardiology)

IMAGING PERFORMED BY

Pamela Harrigan,
RDCS

HOSPITAL NAME

Mass Veterinary
Services

REFERRING VET

Dr. Masloski

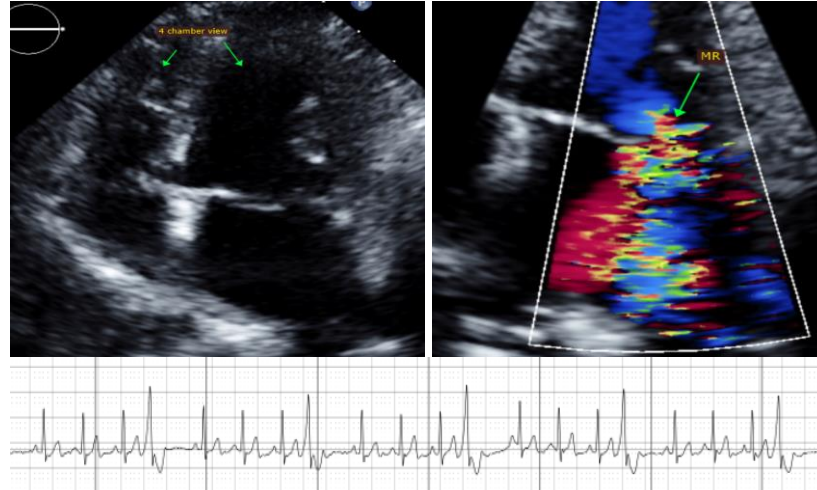
INVOICE

24025

DATE

5/4/22

IMAGES



The information and recommendations provided are based on the images presented by the referring veterinarian. No evaluation can be communicated regarding pathology that was not visible in the image/video clips provided.

Thank you for this referral. This report was generated using transcription software, and minor dictation errors may be present. If the clinical or image interpretation does not parallel your findings or if I can be of any further assistance, please contact me.

Maggie Machen Lamy, DVM
Diplomate of the American College of Veterinary Internal Medicine (Cardiology)
info@sonopath.com

Echocardiogram performed by: Pamela Harrigan, RDCS
Pet Animal Ultrasound Service (4paus.com)